

固定義齒學概論
Introduction to Fixed Prosthodontics

Overview(II)1. Final Impression 2. Bite Registration 3. Provisional Coverage Placement

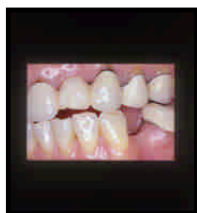台北醫學大學口腔衛生學系
張鴻政
ben888@mail2000.com.tw

學習目標

1. 患者的主訴及預算
2. 治療計畫的擬定
 - 全口復健
 - 局部治療
3. 瞭解病患的個性及工作屬性
 - 患者要求
 - 患者合作程度
4. 患者過去的醫療病史
 - 心臟病、糖尿病、腎臟病、肝病、精神疾病等。
5. 患者是否有口腔功能異常
 - 夜間磨牙、緊咬等。
6. 患者是否存在有咬合干擾
7. 美觀的建立

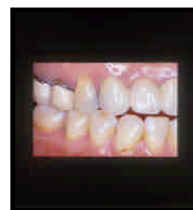Mutually protected articulation

- An occlusal scheme in which the posterior teeth prevent excessive contact of the anterior teeth in maximum intercuspation, and the anterior teeth disengage the posterior teeth in all mandibular excursive movements.

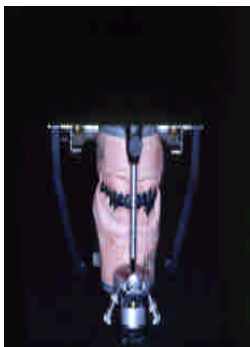

Group function

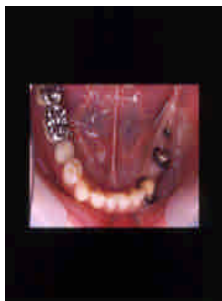- Multiple contact relations between the maxillary and mandibular teeth in lateral movements on the working side where by simultaneous contact of several teeth act as a group to distribute occlusal forces.



Diagnostic wax pattern

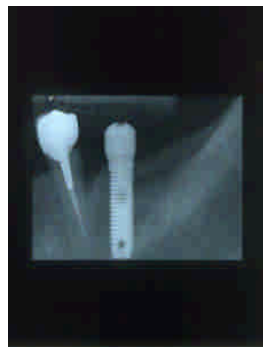

Gingival retraction



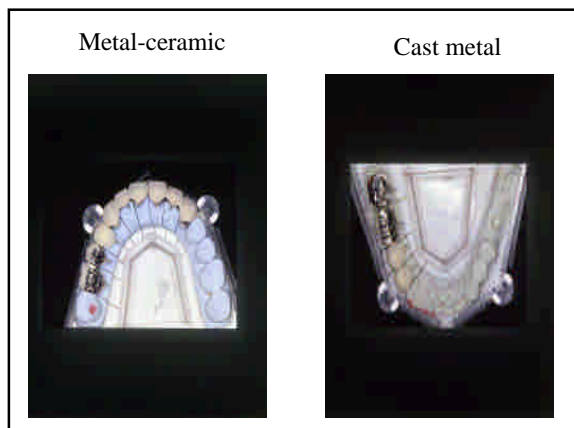
- Displacement of gingival tissues away from the tooth.

Implant-supported prosthesis




Fixed partial dentures






Midline

- The midline refers to the vertical contact interface between two maxillary centrals. It should be perpendicular to the incisal plane and parallel to the midline of the face.



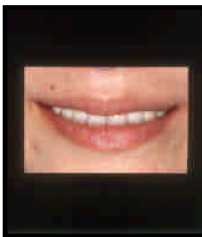
Midline

- The philtrum of the lip is one of the most accurate of these anatomical guideposts.




Smile line

- Refers to an imaginary line along the incisal edges of the maxillary anterior teeth which should mimic the curvature of the superior border of the lower lip while smiling.



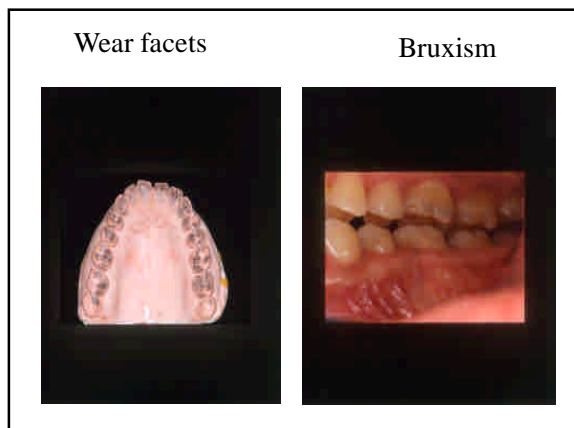
- The lip line is generally considered acceptable within a range of 2 mm. apical or coronal to the height of gingiva of the maxillary centrals.



5. 患者是否有口腔功能異常

- 夜間磨牙、緊咬等。






Central ratio

- Central width determines central length according to an ideal width to length ratio of 4:5 or 0.8 to 1.0. Generally the acceptable range for the width of the centrals is 75% - 80% of their length.


Incisal edge position

- The incisal edges should lightly touch the vermilion border of the lower lip when making F and V sounds.



Incisal embrasures

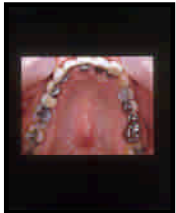
- The incisal embrasures should display a natural, progressive increase in size or depth from the central to the canine.



- The proper incisal edge position is determined by :
 1. Incisal display.
 2. Phonetics : Lip placement during formation of F sounds.
 3. Incisal and occlusal plane.

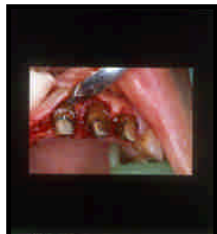Unit

- A bridge is described by the number of units involved. For example, a bridge that replaces one missing tooth is called a three-unit bridge because it consists of three parts (two abutments and a pontic).

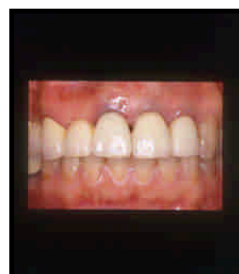

Periodontal health

- Periodontal health must be established prior to placement of final restorations and if at all possible even before commencement of restorative treatment.



- The margins should be at the height of gingiva or not more than 0.5 mm apical to it.

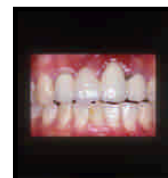

Smile line

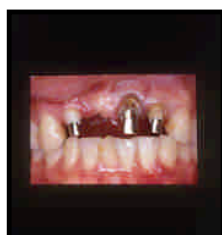- Refers to an imaginary line along the incisal edges of the maxillary anterior teeth which should mimic the curvature of the superior border of the lower lip while smiling.

Margin placement & design

- The healthy gingival sulcus is shallow and can be anywhere from 0.5mm to 1.0mm deep on the facial of anterior teeth. Researchers found that gingival inflammation is related to the level of the crown margin below the gingival crest.

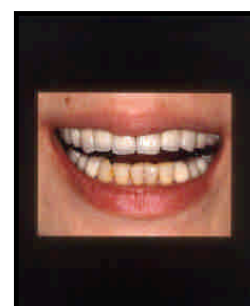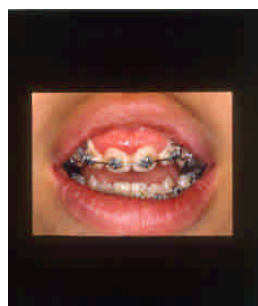


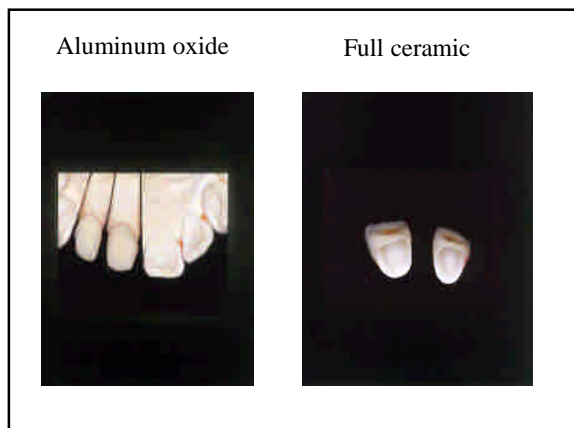
- The restoration margin must maintain a distance from the alveolar crest that respects the biological width; otherwise gingival recession or pocket formation and periodontal disease may ensue.



High lip line


Low lip line






Gingival contour shape and position

- The cervical gingival height (position or level) of the centrals should be symmetrical. it is preferable to exhibit a rise and fall in the soft tissue by having the gingival contour over the laterals located towards the incisal compared to the tissue level on the centrals and canines.

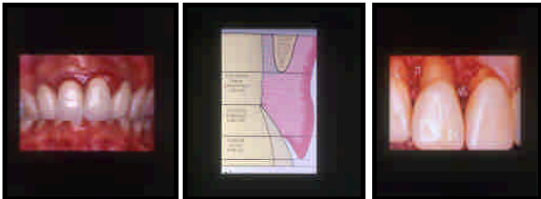


Cervical embrasures

- The darkness of the oral cavity should not be visible in the interproximal triangle between the gingiva and the contact area. If the most apical point of the contact area of the restoration is 5 mm. or less from the crest of bone then black triangles will be avoided.



- The restoration margin must maintain a distance from the alveolar crest that respects the biological width; otherwise gingival recession or pocket formation and periodontal disease may ensue.




Margin placement & design

- The healthy gingival sulcus is shallow and can be anywhere from 0.5mm to 1.0mm deep on the facial of anterior teeth. Researchers found that gingival inflammation is related to the level of the crown margin below the gingival crest.

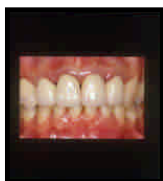Periodontal health

- Periodontal health must be established prior to placement of final restorations and if at all possible even before commencement of restorative treatment.



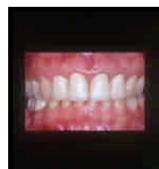Gingival contour shape and position

- The cervical gingival height (position or level) of the centrals should be symmetrical. it is preferable to exhibit a rise and fall in the soft tissue by having the gingival contour over the laterals located towards the incisal compared to the tissue level on the centrals and canines.



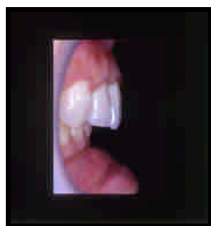Provisional Coverage

- Also known as temporary coverage, The four specific purposes of the provisional coverage are as follows :
 1. Reduce sensitivity and discomfort in the prepared tooth.
 2. Maintain the function and esthetics of the tooth.
 3. Protect the margins of the preparation.
 4. Prevent shifting of the adjacent or opposing teeth.

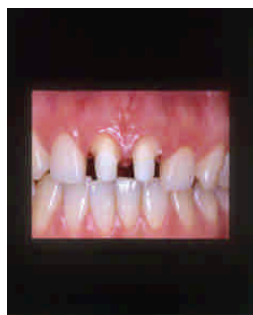

Emergence profile

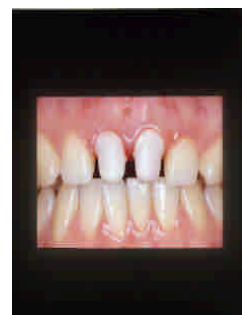- The emergence profile must mimic the silhouette of the natural dentition, in the gingival one third, when viewed from both the facial and lateral views. A proper emergence profile will help avoid swelling and inflammation of soft tissue.



Zirconia post



Aluminum oxide



Provisional Coverage

- 臨時假牙覆蓋所需要了解的大綱有四項它包含：定義、適應症、要求以及形式
- 1. Definition – 定義
- 2. Indication – 適應症
- 3. Criteria – 要求
- 4. Type – 形式：包含依個人製作形式以及現成形式兩種
 1. custom made
 2. preformed

Provisional Coverage

Definition – Provisional Coverage 的定義是指一個臨時保護性的假牙 它的目的是在牙齒修形之後到最後假牙黏著之間提供支台齒的保護，並提供功能及美觀。

temporary protective tooth preparation... final cementation custom (time / fitting, natural looking) 依個人製作的臨時假牙，製作比較費時但能提供比較好的密閉性即自然外觀

preformed 現成的臨時假牙製作比較省時，但密閉性及外觀較差。 不管是個人製作或是現成的臨時假牙都需要製行兩種表面形狀，一種是外在 表面形狀，一種是組織表面形狀

external surface form tissue surface form

Provisional Coverage

Indication – 適應症

臨時覆蓋假牙它的適應症有四大項

1. sensitivity, discomfort 防止修形過後的支台齒敏感及不舒服
2. Margins of preparation 保護修形支台齒的邊緣
3. function, esthetics 提供功能及美觀
4. Shifting of adjacent or opposing teeth 防止鄰接牙或對咬牙移動

Provisional Coverage

Criteria – 臨時覆蓋假牙的要求有六大項

1. esthetics 要美觀
2. margin, fit 邊緣要吻合
3. occlusal surface 咬合面要協調
4. contour 牙齒外形要符合生理形態
5. comfort, stable cementation 配戴要舒適，要穩定黏著
6. readily removed provisional coverage 容易移除

Type – 臨時覆蓋假牙有兩種形式

1. custom made 一種是依個人條件製作
2. preformed 一種是現成的臨時假牙

Provisional Coverage

Type – 種類

1. custom 依個人條件製作的臨時假牙，它所使用的材料可分成三大類 material
 - 1) self-curing acrylic resin 自聚合式壓克力樹脂
 - 2) light-curing composite resin 光聚合式壓克力樹脂 (hybrid)
 - 3) heat-curing acrylic resin 熱聚合式壓克力樹脂 (wax pattern)

Provisional Coverage

Type

1. custom made 依個人條件製作的臨時假牙，它的製作項目有兩種 method
 - 1) external surface form 外表形態的形成可利用以下三種材料
 - (1) alginat
 - (2) silicone
 - (3) cellulose acetate (vacuum)
 - 2) tissue surface form 組織表面形態可利用以下兩種方式形成
 - directed...p't abutment 直接法，是利用病人口腔中的支台齒
 - indirected...cast 間接法，是利用石膏模型上的支台齒

Provisional Coverage

Type

2. preformed 現成的臨時假牙有以下三種材料可以選擇 material
 - 1) polycarbonate 聚碳酸鹽
 - 2) aluminum shell crown 鋁殼冠
 - 3) stainless steel crown 不銹鋼冠
 method 現成製作的臨時假牙，它的製作項目有兩種
 - external surface form 外表形態為現成的
 - tissue surface form 組織表面形態可利用病人口腔中的支台齒來形成
 - directed...p't abutment

Provisional Coverage

Custom acrylic provisional crown 依個人條件製作的壓克力臨時假牙

- 它的外表形態是立即用手製作，它組織表面形態是利用病人口腔中的支台齒來形成
- 的
支
- external surface form
immediate hand made
tissue surface form
p't abutments

Provisional Coverage

Custom acrylic provisional crown

依個人條件製作的臨時假牙，它的外表形態可利用刻臘法，在模型上加以塑形，然後利用矽化物印模材加以複製，它的組織表面形態是利用病人口腔中的支台齒來塑形！

external surface form..wax up
silicone
tissue surface form
p't abutments

Provisional Coverage

Custom acrylic provisional crown

依個人條件製作的壓力臨時假牙，它的外表形態可根據石膏模型上面的牙齒形態，利用纖維素醋酸鹽以熱壓法翻模。組織表面形態可利用兩種方式取得，一種為病人口腔中的支台齒，一種為石膏模型上的支台齒。

external surface form..fixed crowns
cellulose acetate
tissue surface form
p't abutments
cast

Provisional Coverage

Preformed 現成的臨時假牙，它所使用的材料為聚碳酸鹽時，是以病人的口腔內支台齒來形成它的組織表面形態。

material
polycarbonate
method
external surface form
tissue surface form
directed ...p't abutment

Provisional Coverage

Preformed 現成的臨時假牙，它所使用的材料為鋁殼冠時，是以病人的口腔內支台齒來形成它的組織表面形態。

material
aluminum shell crown
method
external surface form
tissue surface form
directed ...p't abutment
• *Home care* 居家保養
brush 牙刷
floss 牙線
interdental floss 牙橋穿引線
interdental brush 齒間刷

Summary

Mutually protected articulation
Group function
Midline
Smile line
Central ratio
Periodontal health
Margin placement & design
Gingival contour shape and position
Cervical embrasures

資料來源

Modern Dental Assisting
DONIL. BIRD and DEBBIES. ROBINSON
SEVENTH EDITION
Fundamentals of Fixed Prosthodontics
Third edition
Herbert T. Shillingburg Jr, DDS
Sumiya Hobo, DDS, MSD, PhD
Lowell D. Whitsett, DDS
Richard Jacobi, DDS
Susan E. Brackett, DDS, MS
Contemporary Fixed Prosthodontics
Third Edition
Rosenetiel.Land.Fujimoto